

# Effect of Quinalphos on Testes of Long Day Seasonal Breeder Golden Hamster, *Mesocricetus auratus*

Jitendra Kumar<sup>1</sup>, Chandana Halder<sup>2</sup>, and Rakesh Verma<sup>3\*</sup>

<sup>1</sup>Department of Zoology, BHU, Varanasi. jitendramouryably@gmail.com

<sup>2</sup>Department of Zoology, BHU, Varanasi. Chaldar2001@yahoo.com

<sup>3</sup>Department of Zoology, BHU, Varanasi. rakeshverma2527@gmail.com

**Abstract:** The Environmental toxicants are emerging factor for male infertility. Thus, the aim of the present study was to investigate the effect of quinalphos on testes of long day seasonal breeder golden hamster, *Mesocricetus auratus*. Hamsters were randomly divided into two groups (n=5): group I-control and group II-quinalphos treated (250µg/kg BW/day, injected intraperitoneally for 14 days). The testicular histoarchitecture, sperm count, sperm viability, antioxidant enzyme activity and lipid peroxidation level of testes were evaluated. Quinalphos treatment altered testicular histoarchitecture and led to reproductive dysfunction as evident by reduced sperm count and sperm viability. Further, quinalphos treated hamsters showed marked decrease in testicular antioxidant enzyme (superoxide dismutase, SOD and catalase, CAT) activities with an increase in lipid peroxidation (MDA) level. In conclusion, our findings clearly suggest that quinalphos exposure induces testicular oxidative stress having negative impact on male reproductive function.

**Key words:** Quinalphos, seasonal breeder, testes, oxidative stress, infertility.

## I. INTRODUCTION

Modern agricultural practices with advancement of technologies are known for high crop yield with intensive use of pesticides that contaminates our environment (Blindauer et al.,1999). Quinalphos (organothiophosphate) has been commonly used pesticide that acts as an endocrine disruptor and may have detrimental effect on the reproductive system (Stone, 1994; Steinmetz et al., 1997). Exposure to quinalphos leads to oxidative stress condition in brain and testes of rat. (Gupta et al., 1998).

Oxidative stress is one of the possible outcomes of pesticide-induced toxicity as it leads to imbalance between antioxidant defense system and the level of reactive oxygen species (ROS). Oxidative stress leads to functional impairment of several physiological processes including reproduction (Cardoso et al., 2019; Mukherjee et al., 2014). Enhanced ROS generation are capable of compromising the testicular steroidogenic as well as spermatogenic activity (Hales et al.,2005; Naughton et al., 2001). Further, a large number of clinical investigations have documented relationship between oxidative stress and male infertility (Sikka, 2001; Agarwal et al., 2006). Environmental toxicity caused by excessive use of pesticides is an emerging issue among reproductive physiologists to unmask the idiopathic causes of male infertility. Recent reports suggest that golden hamster can act as an excellent model for study of testicular toxicity (Ma et al., 2008; Imai and Kitahasi, 2014; Kanimozhi et al., 2014). However, investigations regarding impact of quinalphos on long day seasonal breeder are lacking. Therefore, the aim of the present study was to evaluate the effect of quinalphos induced testicular dysfunction in golden hamster, *Mesocricetus auratus*.

## II. MATERIALS AND METHODS

### A. Animal maintenance

Hamsters were maintained and experiments were performed according to the guidelines of the Animal Ethics Committee of the Banaras Hindu University (IAEC Approval Reference No. BHU/DoZ/IAEC/2018-19/035) as per approval of Committee for the Purpose of Control and Supervision of Experiments on Animals (CPCSEA), Government of India (Departmental animal house Reg. no. 1802/G0/Re/S/15/CPCSEA).Hamsters were kept

under constant temperature ( $25 \pm 2$  °C) and light/dark cycle (Critical photoperiod; 12.5 h light, 11.5 h dark; i.e. lights on 07:00–19:30 h). Animals were maintained in polypropylene cages of equal sizes and provided with commercial rodent pellet and tap water *ad libitum*.

#### B. Chemicals

Quinalphos (CAS No. 1593-03-8) and TBA (CAS No. 504-17-6) was purchased from Sigma-Aldrich. All other chemicals used in the present study were of analytical research grade and purchased from Hi-Media, SRL and Merck, Ltd., Mumbai, India.

#### C. Selection of dose

Dose and mode of administration of Quinalphos (250 µg/kg BW) was selected based on earlier report (Debnath and Mandal, 2000).

#### D. Experimental design

Adult male golden hamsters (average weight  $125 \pm 5$  g, 90–100 days old) were randomly selected and divided into two experimental groups each containing five animals ( $n = 5$  /group).

Group I: Control (vehicle treated, corn oil); Group II: Quinalphos treated (250µg/kg BW/day). All the treatments were given for two-week duration via intraperitoneal route at 10:30 hrs and volume of injected solution was adjusted to 100 µl (Mukherjee et al., 2014). The intraperitoneal route of administration was selected to document the maximum effect of quinalphos as reported earlier (Debnath and Mandal 2000).

#### E. Sample collection and processing

The hamsters were weighed and sacrificed, 24 hrs. (at 10:30 hrs) after the last dose of quinalphos. Testes were immediately removed, blotted dry and weighed. Right testes were quickly fixed in Bouin's solution for histological and left testes were kept at  $-20$  °C for biochemical estimations.

#### F. Sperm parameters (sperm count and viability)

Immediately after sacrificing the animal, one of the epididymis from each animal was dissected out and used for analysis of sperm counting and viability assay. The cauda epididymal sperm count was carried out according to the World Health Organization (1999) laboratory manual. MTT (3-(4, 5-dimethylthiazol-2-yl)-2, 5-diphenyltetrazolium bromide) assay for viability of sperm was performed following the method published elsewhere (Singh and Singh, 2018). Briefly, after the sperm count, the sperm suspension was immediately diluted to obtain a concentration of  $4 \times 10^6$  spermatozoa/ml. In each well of the 96 well plate, 100 µl of diluted sperm suspension and 20 µl of MTT (stock solution 5 mg/ml of MTT in phosphate buffered saline) were placed. This was performed in duplicate. Plate was incubated at 37°C with 5% CO<sub>2</sub> for 1 hour and then 100 µl of acidified propanol (18 µl HCl in 5ml of isopropanol) was added in each well to dissolve the formazan. After 30

minutes, optical density was recorded on a micro plate reader (ELx-800; Biotek Instruments, Winooski VT, USA) at a wavelength of 570 nm.

#### G. Histological and histomorphometric analysis of testes

For histological evaluation, testes were sliced and fixed in Bouin's solution for 22 hours. After fixation, testes slices were washed under running tap-water to remove extra fixative followed by sequential dehydration through graded ethanol series and then cleared in benzene. Tissues were embedded in paraffin and cut into 5 µm sections (RM2245 semi-automatic microtome, Leica, GmBH, Germany). The sections were stretched on clean glass slides pre-coated with 2% gelatin. Deparaffinized sections were stained using hematoxylin and eosin staining. Testicular morphology was observed under microscope (Nikon, E 200, Tokyo, Japan) in randomly selected sections. The diameter and germinal epithelium height were measured of 100 seminiferous tubules from 10 sections of testes on glass slides.

#### H. Measurement of testicular antioxidant status

Testes were homogenized in ice cold PBS (50mmol, pH 7.4) to obtain 10% homogenate which was centrifuged at 12,000×g for 30 min to obtain the supernatant and protein levels were estimated using BSA as the standard (Bradford, 1976). The supernatant was used for measurement of antioxidant status.

SOD activity was analyzed following method described elsewhere (Das et al., 1999) with minor modifications (Mukerjee et al., 2014). Briefly, 0.5ml of homogenate was added to 1.4ml of reaction mixture comprising of 50 mmol phosphate buffer (pH 7.4), 20 mmol L-Methionine, 1% (v/v) Triton X-100, 10 mM Hydroxylamine hydrochloride, 50 mmol ethylene diamine tetraacetic acid (EDTA) followed by a brief pre-incubation at 37 °C for 5 min. Next, 50 µM of riboflavin was added under red light to all samples along with control containing buffer instead of sample and then exposed to two 20 W fluorescent lamps fitted parallel to each other in an aluminum foil coated wooden box. After 10 min of exposure, 1 ml of freshly prepared Greiss reagent (1% sulphanilamide, 5% orthophosphoric acid, 0.1% N-1-naphthylethylenediamine dihydrochloride) was added and absorbance of the color formed was measured at 543 nm. SOD activity was expressed as units (U)/mg of protein.

Catalase (CAT) activity was measured according to method published elsewhere (Sinha, 1972) with minor modifications (Mukerjee et al., 2014). Briefly, 5ml of PBS was mixed with 4 ml of H<sub>2</sub>O<sub>2</sub> (0.8 mmol) and then 1 ml testicular homogenate was added into it. After 1 min, 1 ml of this solution was taken in a tube, and 2 ml of acidic potassium dichromate (K<sub>2</sub>Cr<sub>2</sub>O<sub>7</sub>) solution was added. Then, the mixture was boiled for 10 min and absorbance of the color formed was measured at 570 nm. The activity of CAT was expressed as amount of H<sub>2</sub>O<sub>2</sub> depleted /min/mg of protein. Standard curve was calibrated with varying concentrations of 0.2M H<sub>2</sub>O<sub>2</sub> serially diluted in PBS.

Lipid peroxidation (LPO) was measured by estimation of MDA level following the method published elsewhere (Ohkawa et al., 1978) with minor modifications (Mukherjee et al., 2014). Briefly, In 3.3 ml of thiobarbituric acid (TBA) reagent (0.2 ml of 8% sodium dodecyl sulphate, 1.5 ml of 20% acetic acid of pH 3.5, 1.5 ml of 0.8% TBA and 0.1 ml of 0.8% Butylated Hydroxy Toluene (BHT), 0.2 ml of supernatant was mixed and incubated at 95°C in a water bath for 60 min. The reaction mixture was then brought to room temperature and centrifuged at 500 g for 10 min at 4 °C. The OD of supernatant was recorded at 532nm. The LPO was expressed as nmol MDA/mg protein.

**I. Measurement of ROS level of sperm**

The cellular reactive oxygen species (ROS) level of sperm was measured using 2',7'-Dichlorodihydrofluorescein-diacetate (DCFH-DA) dye. The sperm was isolated from epididymis, counted and mixed with the DCFH-DA dye, and viewed in a fluorescent microscope (Motic BA410) at 485 nm excitation wavelength and 530nm emission wavelength according to published method elsewhere (Verma et al., 2017). The percentage of DCF intense sperm were counted for 200 sperms in every sample.

**J. Statistical analysis**

Statistical analysis of the data was performed using Graph Pad Prism 8 (USA) with unpaired t-test. The differences were considered statistically significant when  $P < 0.05$ .

**III. RESULTS**

**A. Effect of quinalphos on body weight and relative testicular weight**

A significant ( $P < 0.05$ ) decrease in body weight (BW) was recorded in hamsters exposed to quinalphos as compared to control (Fig.1a). A significant ( $P < 0.05$ ) decrease in relative testicular weight was recorded in hamsters exposed to quinalphos as compared to control (Fig.1b).

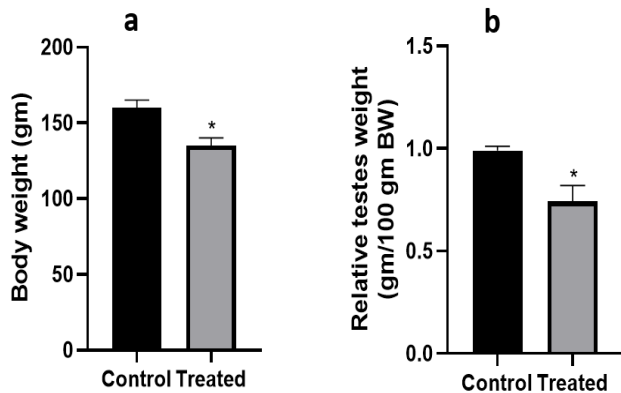


Fig.1. Effect of quinalphos on body weight (BW) and relative testicular weight (RTW) of golden hamster, *M. auratus*. (a) body weight and (b) relative testicular weight. Values are expressed as mean ± SEM

( $n = 5$ ) for control and quinalphos treated group. Significance of difference: \*  $P < 0.05$ , Control versus quinalphos treated group.

**B. Effect of quinalphos on sperm count and viability**

A significant ( $P < 0.05$ ) decrease in sperm count and sperm viability was observed in quinalphos treated group as compared to control (Fig.2a & 2b).

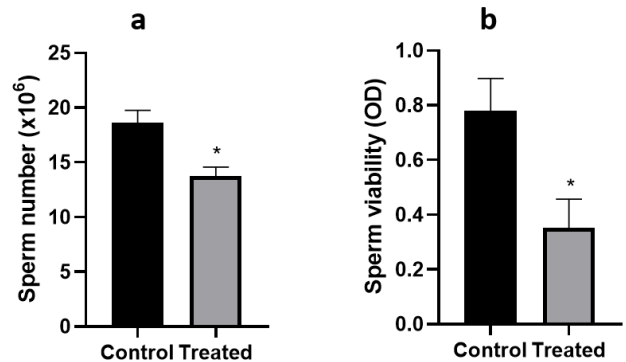


Fig.2 Effect of quinalphos on sperm count and sperm viability of golden hamster, *M. auratus*. (a) sperm count and (b) sperm viability. Values are expressed as mean ± SEM ( $n = 5$ ) for control and quinalphos treated group. Significance of difference: \*  $P < 0.05$ , control versus quinalphos treated group.

**C. Effect of quinalphos on testicular histoarchitecture**

Histological assessment showed normal histoarchitecture of the seminiferous tubule and germinal epithelium along with normal spermatogenesis in the control group (Fig.3a & 3b), while quinalphos treated group showed marked degenerative changes in testes as evident by presence of vacuolization and absence of spermatozoa in the lumen of seminiferous tubule (Fig.3c & 3d).

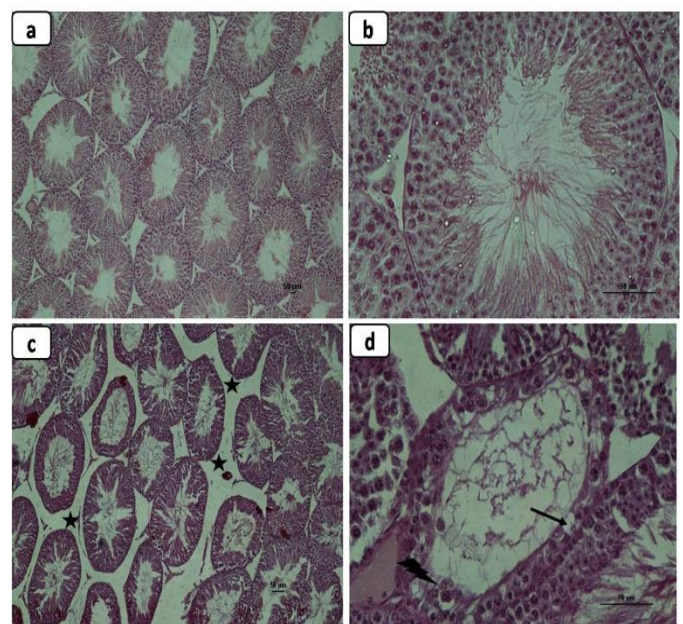


Fig.3. Effect of quinalphos on histological changes (H & E staining) in the testes of golden hamster, *M. auratus*. Photomicrograph (a & b)

normal histoarchitecture of seminiferous tubule and presence of spermatozoa with sequentially arranged germ cells in control. (c & d) quinalphos induced alterations in the testes having cellular vacuolization, giant cell, Leydig cell atrophy and lumen without sperm. Where “arrow” indicates vacuole ‘arrow head’ indicates giant cell and star indicates increased interstitial space. Original magnifications at x100 (for a & c) and x400 (for b & d) respectively.

**D. Effect of quinalphos on testicular histomorphometry**

Significant ( $P < 0.05$ ) decrease in seminiferous tubule diameter was observed in quinalphos treated group when compared to the control while significant increase in seminiferous tubule lumen diameter was noted in quinalphos treated animal as compared to control (Fig. 4a & 4b). Further, a significant ( $P < 0.05$ ) decrease in area of seminiferous tubule and height of germinal epithelium was noted in quinalphos treated group when compared to the control (Fig. 4c & 4d).

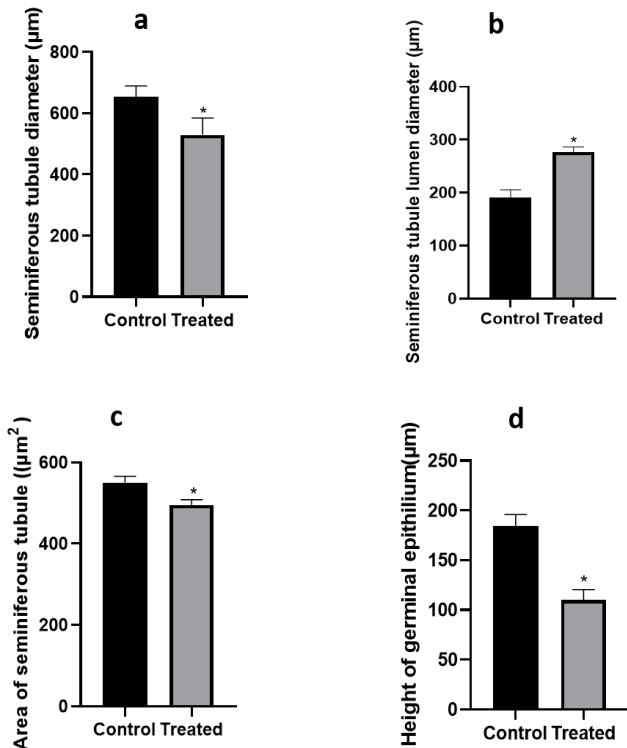


Fig.4. Effect of quinalphos on testicular histomorphometry. (a) seminiferous tubule diameter, (b) seminiferous tubule lumen diameter, (c) area of seminiferous tubule and (d) germinal epithelium height. Values are expressed as mean  $\pm$  SEM ( $n = 5$ ) for control and quinalphos treated group. Significance of difference: \*  $P < 0.05$ , control versus quinalphos treated group.

**E. Effect of quinalphos on testicular antioxidant enzyme activity**

A significant ( $P < 0.05$ ) decrease in testicular superoxide dismutase (SOD) and catalase (CAT) enzyme activity were observed in quinalphos treated group when compared to control (Fig.5a& 5b).While, a significant ( $P < 0.05$ ) increase in lipid

peroxidation level (MDA concentration) was observed in quinalphos treated group when compared to control (Fig. 5c).

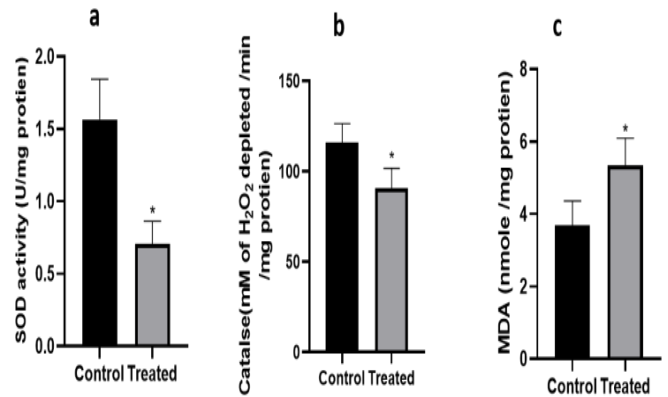


Fig.5. Effect of quinalphos on testicular antioxidant status of golden hamster, *M. auratus*. (a) Superoxide dismutase (SOD) activity, (b) catalase activity and (c) lipid peroxidation level. Values are expressed as mean  $\pm$  SEM ( $n = 5$ ) for control and quinalphos treated group. Significance of difference: \*  $P < 0.05$ , control versus quinalphos treated group.

**F. Effect of quinalphos on sperm ROS level**

A significant ( $P < 0.05$ ) increase in sperm ROS levels were observed in quinalphos treated group when compared to control (Fig. 6).

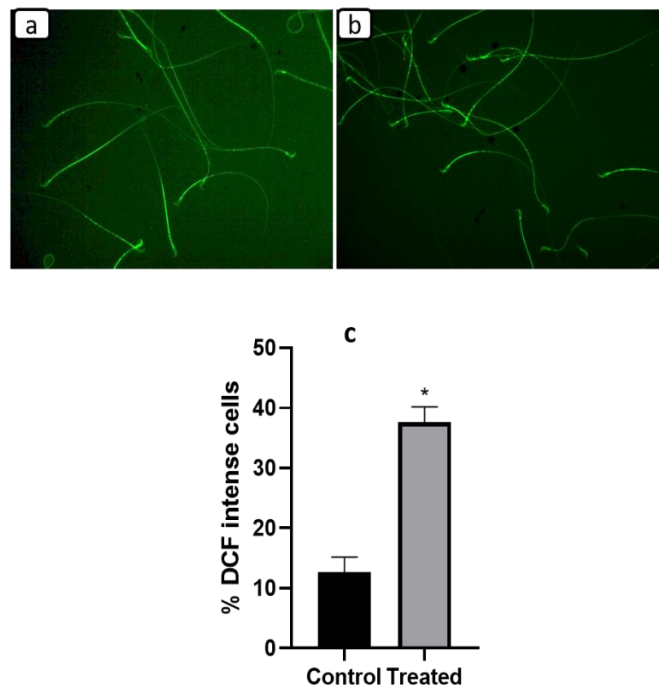


Fig.6. Effect of quinalphos treatment on ROS level of sperm of golden hamster, *M. auratus*. (a) DCFDA stain sperm of control group, (b) DCFDA stain sperm of quinalphos treated group, (c) percentage (%) of intense DCF fluorescent sperm. Values are expressed as mean  $\pm$  SEM ( $n = 5$ ) for control and quinalphos treated group. Significance of difference: \*  $P < 0.05$ , control versus quinalphos treated group.

## IV. DISCUSSION

Seasonal breeders experience marked variation in environmental conditions that act as cue for their reproductive success and survival of their offsprings. Long day breeders are those animals that breeds when the length of light phase of day are longer that generally falls during summer season. Golden hamster, *Mesocricetus auratus* is a long day breeder and have been extensively used for investigating the effect of various chemicals and photoperiodic signals that regulates reproductive functions (Verma and Haldar, 2016; Mukherjee et al., 2014). Under laboratory conditions, golden hamster remains sexually active when they are exposed to photoperiod (length of light duration) more than 12.5 hrs that act as critical photoperiod to maintain reproductive functions.

Environment gets contaminated with excessive use of various chemical and toxicants that have hazardous effect on humans as well as animals. Quinalphos is one of the commonly used pesticide in agricultural fields. The findings of our present study documented the detrimental effect of quinalphos on testes as evident by marked decrease in relative testicular weight of quinalphos treated hamsters. The testicular damage caused by quinalphos was further demonstrated by marked testicular regression and decreased seminiferous tubule diameter. The present study documented testicular degenerative changes such as presence of large number of vacuoles in germinal epithelium, giant cells and lumen devoid of spermatozoa. The presence of giant cells and vacuoles within the seminiferous epithelium are associated with dilated endoplasmic reticulum, mitochondria and perinuclear space that represents impaired spermatogenesis and phagocytosis of defective germ cells (Elnaga et al, 2018, Gupta et al., 1998; Ray et al., 1987; Barlow and Sullivan 1982; Working et al.; 1985; Datta and Dikshith 1976). Earlier report suggests that quinalphos exposure leads to marked decline in androgen level (Ray et al., 1987). Further, we have also documented marked decrease in epididymal sperm count and number of viable sperm that clearly indicates negative impact of quinalphos on spermatogenic cycle and sperm maturation.

Oxidative stress is a major cause for male infertility (Asadi et al, 2017) and hence received much attention in the area of reproductive toxicology. Imbalances between reactive oxygen species (ROS) and antioxidant enzyme system lead to oxidative stress condition in tissues. In this regard, antioxidant enzymes such as superoxide dismutase (SOD) and catalase (CAT) play an important role by neutralizing ROS and therefore preventing oxidative load (Rastogi and Haldar 2018; Mukherjee et al., 2014). To explore the effect of quinalphos on cellular reactive oxygen species (ROS) level and its neutralization through antioxidant defense system, we have investigated the testicular antioxidant enzyme activities that showed a marked decrease in SOD, CAT activity and marked increase in lipid peroxidation level. Further, we have also documented marked increase in sperm ROS level in quinalphos treated hamsters when compared

to control. Therefore, our present study demonstrates that oxidative stress is a potent mediator of quinalphos induced testicular dysfunction in male golden hamster during their breeding phase which is important period for their species perpetuation and survival (Fig.7). Hence, exposure to such chemicals can severely impair male reproductive health and lead to male infertility.

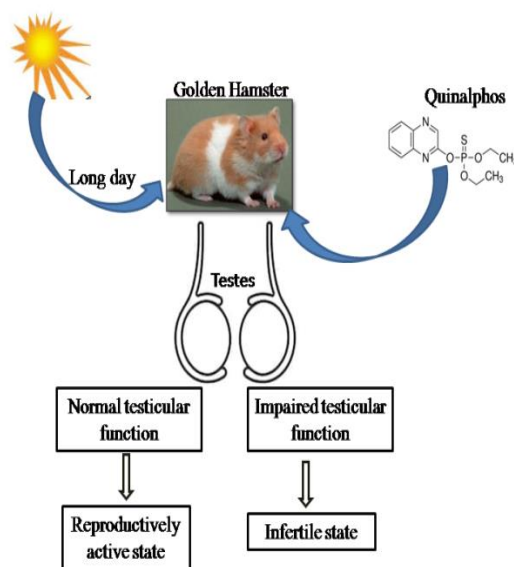


Fig. 7. Effect of quinalphos treatment on testicular function and reproductive status of male golden hamster, *Mesocricetus auratus*.

## ACKNOWLEDGEMENT

The authors are thankful to the Council of Scientific and Industrial Research (CSIR), New Delhi, Government of India for providing financial assistance as Junior Research Fellowship (JRF) to Mr. Jitendra Kumar (grant scheme number: 09/013/(0709)/2017-EMR-I) and the University Grants Commission, New Delhi, India for CAS grant to Department of Zoology, Banaras Hindu University. The instrument subsidiary award from the Alexander von Humboldt Foundation, Bonn, Germany to Prof. Chandana Haldar is gratefully acknowledged.

## REFERENCES

- Aboul-Enein A M, Aboul-Soud, H M A, Said K, 2012. "Hepatoprotective effects of antioxidants against non-target toxicity of the bio-insecticide spinosad in rats,". African J. of Pharmacy and Pharmacol; 6, 8, 550–559.
- Agarwal A, Gupta S, Sikka S, 2006. The role of free radicals and antioxidants in reproduction. Curr Opin Obstet Gynecol; 18: 325–332.
- Asadi N, Bahmani M, Kheradmand A, Rafieian-Kopaei M, 2017. The Impact of Oxidative Stress on Testicular Function and the Role of Antioxidants in Improving it: A Review. J. Clin Diagn Res 11(5): IE01-IE05.

- Barlow S M and Sullivan FM, 1982. In Reproductive Hazards of Industrial Chemicals. Academic Press, London; 253–268.
- Blindauer K M, Jackson R J, Geehin M, Pertowski C, and Rubin C. 1999. “Environmental pesticide illness and injury: The need for a national surveillance system,” J. of Environ Health; 61, 9-10..
- Bradford MM, 1976. A rapid and sensitive method for the quantitation of microgram quantities of protein utilizing the principle of protein-dye binding. Anal Biochem, 72: 248–254.
- Cardoso JP, Cocuzza M, Elterman D, 2019. Optimizing male fertility: oxidative stress and the use of antioxidants. World J. Urol; 37(6): 1029-1034.
- Das K, Samanta L, Chainy NBG, 1999. A modified spectrophotometric assay of superoxide dismutase using nitrite formation by superoxide radicals. Ind J. Biochem Biophys; 37:201–204.
- Datta K K and Dikshith T S S, 1973. Histopathologic changes in the testis and liver of rats repeatedly exposed to pesticides. Exp. Pathol; 8, 363–370.
- Debnath D, Mandal T K, 2000. Study of Quinalphos (an Environmental Oestrogenic Insecticide) Formulation (Ekalux 25 E.C.)-induced Damage of the Testicular Tissues and Antioxidant Defence Systems in Sprague-Dawley Albino Rats. J. Appl. Toxicol; 20, 197–204.
- Elnaga, A AA, Kassab, A A, Soliman, G M, & El Shal, A O, 2018. Histological and immunohistochemical study of the effect of tramadol on the seminiferous tubules of adult albino rat and the effect of its withdrawal. Tanta Medical Journal; 46(1), 38-53.
- Gupta A, and Shukla G S, 1998. Effects of neonatal quinalphos exposure and subsequent withdrawal on free radical generation and antioxidative defenses in developing rat brain. J. Appl. Toxicol; 18, 71–77 .
- Hales D B, Allen J A, Shankara T, 2005. Mitochondrial function in Leydig cell steroidogenesis. Ann N Y Acad Sci; 1061, 120–134.
- Imai T, Kitahashi T, 2014. A 13-week toxicity study of acrylamide administered in drinking water to hamsters. J Appl Toxicol; 34:57–65.
- Kanimozhi V, Palanivel K, Kadalmani B, Krikun G, Taylor HS, 2014. Apolipoprotein E induction in Syrian hamster testis following tributyltin exposure: a potential mechanism of male infertility. ReprodSci; 21:1006–1014.
- Ma A, Yang X, Wang Z, Shi D, Chen Y, 2008. Adult exposure to diethylstilbestrol induces spermatogenic cell apoptosis in vivo through increased oxidative stress in male hamster. Reprod Toxicol; 25:367–373.
- Mukherjee A, Haldar C, Vishwas DK, 2014. Melatonin prevents dexamethasone- induced testicular oxidative stress and germ cell apoptosis in golden hamster, *Mesocricetus auratus*. Int J. Androlxx : 1–12.
- Naughton C K, Nangia A K, Agarwal A, 2001. Pathophysiology of varicoceles in male infertility. Hum Reprod Update; 7: 473–481.
- Ohkawa H, Ohishi N, Yagi K, 1978. Reaction of linoleic acid hydroperoxide with thiobarbuteric acid. J Lipid Res. 19:1053–1057.
- Rastogi S, &Haldar C, 2018. Comparative effect of melatonin and quercetin in counteracting LPS induced oxidative stress in bone marrow mononuclear cells and spleen of *Funambulus pennant*. Food Chem Toxicol; 120: 243-252. doi: 10.1016/j.fct.2018.06.062.
- Ray A, Chatterjee S, Bagchi P, Das T K and Deb C, 1987. Effect of quinalphos on testicular steroidogenesis in rats. Andrologia; 20, 163–168.
- Sikka S C, 2001. Relative impact of oxidative stress on male reproductive function. Curr Med Chem.; 8:851–862.
- Singh S, & Singh SK, 2018. Chronic exposure to perfluorononanoic acid impairs spermatogenesis, steroidogenesis and fertility in male mice. J Appl Toxicol; 39(3):420-431.
- Sinha AK, 1972. Colorimetric assay of catalase. Anal Biochem 47: 389–394.
- Steinmetz R, Brown N G, Allen D L, Bigsby R M and Ben-Jonathan N, 1997. The environmental estrogen Bisphenol A stimulates prolactin release in vitro and in vivo. J. of Endocrinology; 138, 1780–1786.
- Stone R, 1994. Environmental estrogens stir debate. J. of Science; 265, 308–310.
- Verma R , Pal S, Kumar J and Haldar C, 2007. Ultraviolet A (UV-A) Radiation-Induced Damage in the Skin and Vital Organs of Albino Rat: An Indirect Correlation with Melatonin. Journal of Endocrinol and Reprod; 21(2), 1-14. DOI: 10.18311/jer/2017/21626.
- Verma R, Haldar C, 2016. Photoperiodic modulation of thyroid hormone receptor (TR- $\alpha$ ), deiodinase-2 (Dio-2) and glucose transporters (GLUT 1 and GLUT 4) expression in testis of adult golden hamster, *Mesocricetus auratus*. J Photochem Photobiol; 165: 351–358.
- Working P K, Bus J S and Hamm T E, 1985. Reproductive effects of inhaled methylchloride in the male Fischer rats. Toxicol. Appl. Pharmacol. 77, 144–157.